



[Authoritative facts](#) about the skin from the [New Zealand Dermatological Society Incorporated](#).

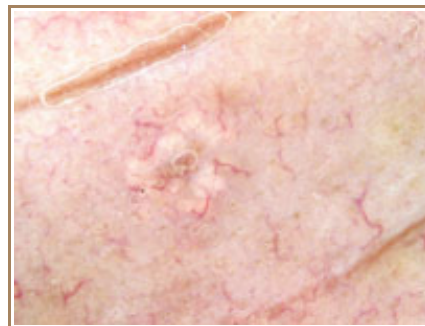
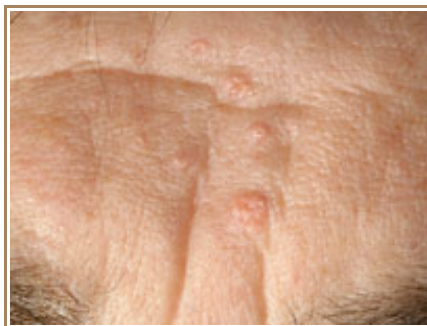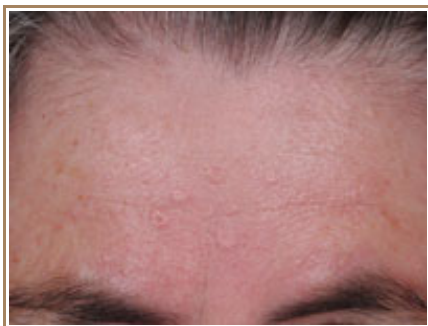[Home](#) | [Acne](#)

Sebacous hyperplasia

Sebacous hyperplasia is the term used for enlarged [sebaceous glands](#) seen on the forehead or cheeks of the middle-aged and elderly. Sebacous hyperplasia appears as small yellow bumps up to 3 mm in diameter. Close inspection reveals a central hair follicle surrounded by yellowish lobules. There are often prominent blood vessels.

The sebaceous hyperplasia lesions are sometimes confused with [basal cell carcinoma](#).

Sebacous hyperplasia



Dermoscopy view

Treatment

Sebacous hyperplasia is harmless and does not require any treatment. However, individual lesions may be removed by light cauterly, diathermy or [laser](#) vaporization.

When the lesions are severe, extensive or disfiguring, oral [isotretinoin](#) or, in females, [antiandrogens](#), may help improve the appearance.

Related information

On DermNet NZ:

- [Acne](#)
- [Seborrhoea](#)
- [Sebum](#)
- [Fordyce spots](#)

Other websites:

[Sebacous hyperplasia](#) - medicine dermatology, the online textbook

Books about skin diseases:

See the [DermNet NZ bookstore](#)

Author: [Dr Amanda Oakley](#) MBChB FRACP, Dept of Dermatology Health Waikato

DermNet does not provide an on-line consultation service.

If you have any concerns with your skin or its treatment, see a [dermatologist](#) for advice.

Created 1999. Last updated 25 Dec 2006. © 2007 NZDS. Disclaimer.