



[Authoritative facts](#) about the skin from the [New Zealand Dermatological Society Incorporated](#).

[Home](#) | [Deep skin disorders](#)

## Jessner lymphocytic infiltrate

### What is Jessner lymphocytic infiltrate?

---

Jessner lymphocytic infiltrate is an uncommon skin condition that presents as non-scaly red patches and lumps on the face, neck and upper back. They are usually painless and do not itch. Lesions may go through periods of remission and exacerbation over months or years. Total spontaneous resolution has also occurred in some cases.

The condition is known by many other names including benign lymphocytic infiltration, Jessner disease, Jessner-Kanof syndrome, and benign chronic T-cell infiltrative disorder. It has been thought to be in the same disease spectrum as [lupus erythematosus](#) but on histology, monoclonal antibody Leu 8 staining indicates they are separate conditions.

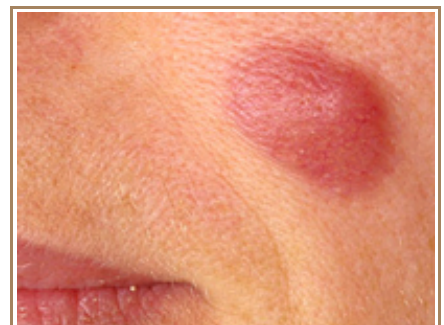
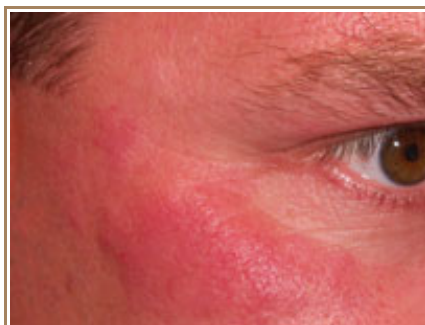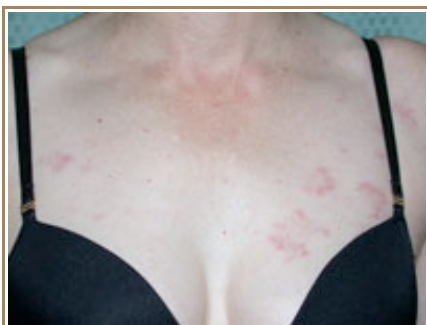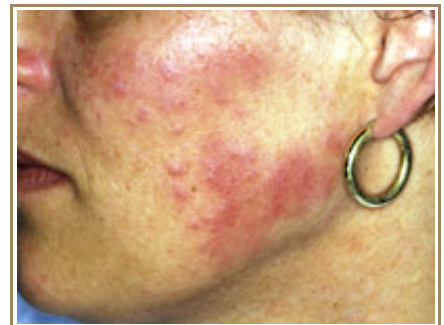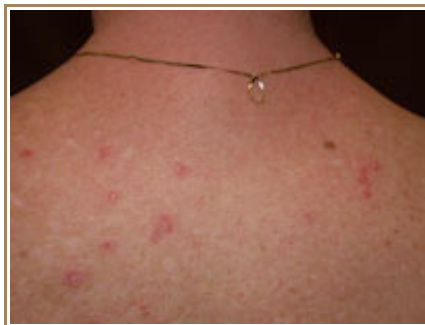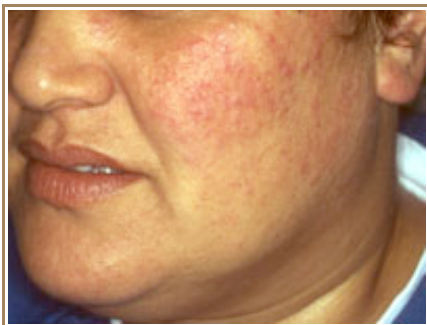The cause of Jessner lymphocytic infiltrate is unknown.

### What are the signs and symptoms?

---

Lesions usually start off as defined, small, slightly raised red spots that gradually enlarge peripherally to create a well demarcated red plaque. Sometimes the centre of the lesion is left clear. Single or multiple lesions may occur and they range from 2mm to 2cm in diameter. Seasonal activity is variable: more patients deteriorate in winter than summer and there may be a relationship with sun exposure. Usually they are symptomless but some patients may complain of itching or burning.

#### Jessner lymphocytic infiltrate



### What treatment is available?

---

Usually no treatment is necessary as after persisting for several months or years, lesions disappear spontaneously without causing other problems. Occasionally they may recur at the same site or elsewhere.

[Cosmetic camouflage](#) may be used to hide lesions and improve appearance. There is variable response to the following treatments:

- [Topical and intralesional corticosteroids](#)
- Antimalarial medications such as [hydroxychloroquine](#)
- Photochemotherapy ([PUVA](#))
- [Radiotherapy](#)

All patients should be advised to follow sun protection measures, regardless of their history of photo-aggravation.

#### Related information

---

##### References:

- Book: Textbook of Dermatology. Ed Rook A, Wilkinson DS, Ebling FJB, Champion RH, Burton JL. Sixth edition. Blackwell Scientific Publications.

##### On DermNet NZ:

- [Facial rashes](#)
- [Polymorphous light eruption](#)
- [Cutaneous lupus erythematosus](#)

##### Other websites:

- [Jessner lymphocytic infiltrate of the skin](#) - emedicine dermatology, the online textbook

##### Books:

See the [DermNet NZ bookstore](#)

**Author:** Vanessa Ngan, staff writer

DermNet does not provide an on-line consultation service.

If you have any concerns with your skin or its treatment, see a [dermatologist](#) for advice.

Created 2003. Last updated 25 Dec 2006. © 2007 NZDS. Disclaimer.