



[Authoritative facts](#) about the skin from the [New Zealand Dermatological Society Incorporated](#).

[Home](#) | [Deep skin disorders](#) |  [Deep skin disorders: PDF 73 KB](#)

## Relapsing polychondritis

### What is relapsing polychondritis?

---

Relapsing polychondritis is a rare autoimmune disorder characterised by recurrent episodes of inflammation and destruction of cartilaginous tissues.

### What are the symptoms of relapsing polychondritis?

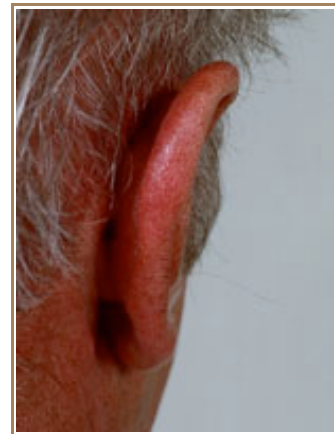
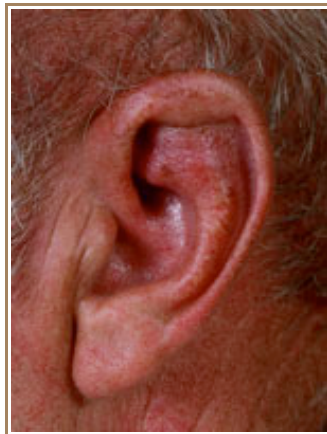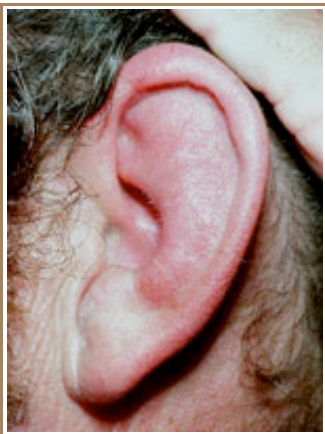---

Relapsing polychondritis most commonly presents as inflammation of the cartilage of the ears and nose.

- Inflammation of the cartilage of the ears, with red ears resembling infectious cellulitis, is the most common finding. The ear lobes, containing no cartilage, are classically spared by the inflammation. Chronic disease may result in a flabby, droopy ear or in a "cauliflower" ear.
- Involvement of the nose may result in saddle nose deformity.
- Acute involvement of the cartilage of the trachea (wind pipe) may cause collapse of the airway with obstruction and subsequent lung infections.
- Arthritis may affect one joint or more than one joint, most often the cartilaginous junctions of the ribs.
- Other manifestations may include damage to the heart valves, nervous system, eye and kidney disease.

#### Relapsing polychondritis

---



### What is the cause of relapsing polychondritis?

---

Antibodies to type 2 collagen in cartilage are found. As with other autoimmune diseases, exactly why these antibodies form is not known.

### Investigations

---

A blood screen shows signs of inflammation. Antibody to type 2 collagen may be measured by certain specialist

laboratories.

A tissue biopsy shows inflammation in the cartilage.

## Management

---

**Systemic corticosteroids** (e.g. prednisone) remain the mainstay of treatment. Other treatments that are sometimes prescribed include:

- nonsteroidal anti-inflammatories
- [dapsons](#)
- [colchicine](#)
- [azathioprine](#)
- [methotrexate](#)
- [cyclophosphamide](#)
- [hydroxychloroquine](#)
- [ciclosporin](#)
- [infliximab](#).

*Draft 9 March 2008*

### Related information

---

#### References:

- Relapsing polychondritis, Rapini RP, Warner NB, Clin Dermatol. 2006 Nov-Dec; 24(6):482-5. Review. [Medline](#).

#### On DermNet NZ:

#### Other websites:

- [Relapsing Polychondritis](#) - emedicine dermatology

#### Books about skin diseases:

See the [DermNet NZ bookstore](#)

**Author:** Dr Mark Duffill, Hamilton

DermNet does not provide an on-line consultation service.

If you have any concerns with your skin or its treatment, see a [dermatologist](#) for advice.

Created 2008. Last updated 08 Mar 2008. © 2008 NZDS. Disclaimer.