



[Authoritative facts](#) about the skin from the [New Zealand Dermatological Society Incorporated](#).

[Home](#) | [Skin signs of systemic disease](#)

## Crohn skin disease

Crohn disease is an inflammatory bowel disease that involves inflammation of the small intestine. This can cause pain, fever, constipation, diarrhoea and weight loss. Extraintestinal features are common in Crohn disease and include arthritis, skin problems, inflammation in the eyes or mouth, gallstones and kidney stones. Skin lesions are often seen in patients with Crohn disease. When granulomatous lesions of Crohn disease involve sites other than the gastrointestinal tract then the disease is then termed metastatic Crohn disease.

### What are the signs and symptoms?

Skin involvement occurs in about 40% of patients with Crohn disease. Often the involvement is an extension of the intestinal disease and presents as fissures and abscesses around the perineal and perianal region. However, any part of the skin can be affected. Lesions may present as spots or plaques found on the trunk, arms and legs, and they may be mildly itchy. In some cases distinctive dermatoses are present. These include:

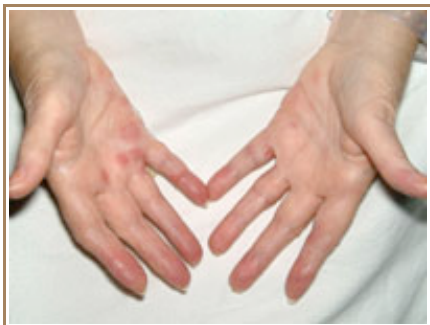- [Pyoderma gangrenosum](#)
- [Erythema multiforme](#)
- [Erythema nodosum](#)
- Necrotizing small vessel [vasculitis](#).

Occasionally, skin lesions may occur before any signs or symptoms of the intestinal disease.

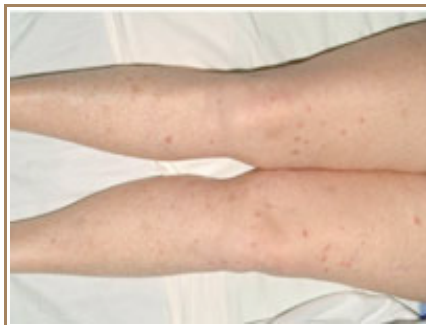Oral involvement occurs in 8–9% of Crohn disease and includes:

- Gingival or mucosal swelling
- Cobblestoning of the buccal mucosa
- [Aphthous ulcers](#)
- Mucosal tags
- Angular cheilitis
- [Granulomatous cheilitis](#)

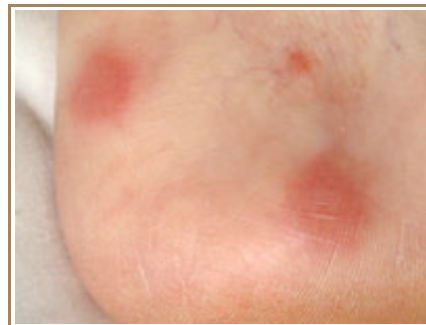### Skin complications of Crohn disease



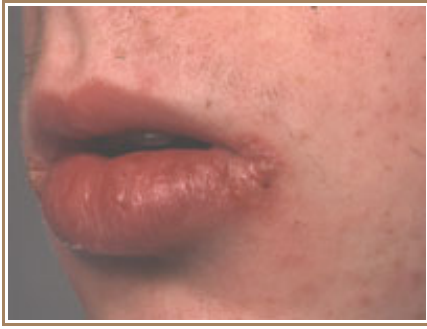\*



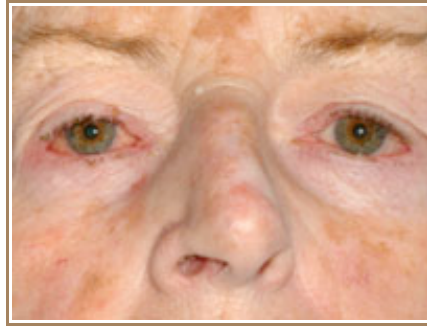\*



\*

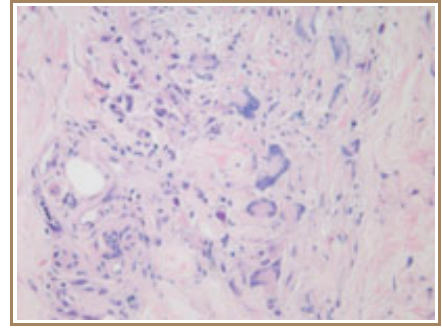


Granulomatous cheilitis



Episcleritis

\*



Granuloma on skin pathology

\*

\* Images from: Sheikh A, Aldameh A, Symmans P, Hill A. New Zealand Medical Journal. 2006;119(1247). URL: <http://www.nzma.org.nz/journal/119-1247/2363/> (with permission)

## Diagnosis of Crohn skin disease

**Skin biopsy** of the lesion is performed. Under microscopy, the presence of non-caseating granulomas similar to those found in intestinal Crohn disease supports the diagnosis of Crohn skin disease. In patients with no intestinal disease whose skin biopsy come up with non-caseating granulomas, a thorough gastrointestinal history and work-up should be performed.

## What is the treatment of Crohn skin disease?

Treatment for Crohn skin disease is palliative not curative. Treatment of the intestinal manifestations usually improves the skin lesions. These may include [oral corticosteroids](#), [azathioprine](#), sulfasalazine and new anti tumour necrosis factor agents such as infliximab.

### Related information

#### References:

Book: Textbook of Dermatology. Ed Rook A, Wilkinson DS, Ebling FJB, Champion RH, Burton JL. Fourth edition. Blackwell Scientific Publications.

#### On DermNet NZ:

#### Other websites:

- [Oral Manifestations of Systemic Diseases](#) - e-medicine dermatology, the online textbook

#### Books:

See the [DermNet NZ bookstore](#)

**Author:** Vanessa Ngan, staff writer

DermNet does not provide an on-line consultation service.

If you have any concerns with your skin or its treatment, see a [dermatologist](#) for advice.

Created 2003. Last updated 26 Dec 2006. © 2008 NZDS. Disclaimer.