



[Authoritative facts](#) about the skin from the [New Zealand Dermatological Society Incorporated](#).

[Home](#) | [Vascular skin problems](#)

## Venous malformation

Venous malformations are a type of vascular naevus or [birthmark](#). They are due to malformed dilated veins and are non-cancerous. They appear as skin coloured, blue or purple swellings on any part of the body, and there are often prominent veins near the skin surface. Like [capillary vascular malformations](#) (port wine stains), venous malformations are always present at birth, although they may become more obvious with time. They may vary in size from a small dot to occasionally involving a whole limb. Unlike cavernous [haemangiomas](#), they grow in proportion to the child's general growth.

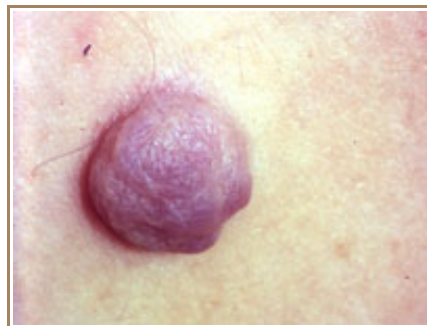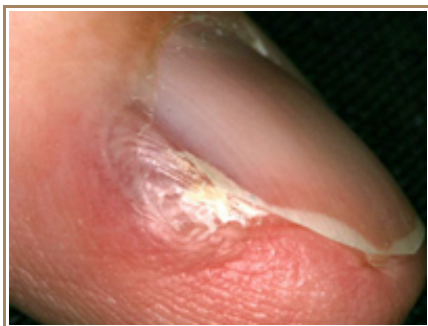
### Glomuvenous malformations

---

Glomuvenous malformations are also known as glomangioma or multiple glomus tumours. They differ from standard venous malformations by raised, blue or bluish-purple and cobblestone appearance. They are often tender lesions. There are characteristic features of this lesion on [skin biopsy](#) (histology). Glomuvenous malformations are inherited as an autosomal dominant trait, which means half the children of an affected person will have a tendency to develop these lesions to a variable extent. They are due to a specific mutation in the glomulin gene.

Glomuvenous malformations should be distinguished from solitary glomus tumours, which usually occur under or beside a nail in an adult, and are not inherited. They are small tender blue or purple nodules with a fibrous rim. An x-ray may show underlying erosion of the bone. Solitary glomus tumours are due to a proliferation of glomus cells; the diagnosis is confirmed by [skin biopsy](#).

#### Solitary glomus tumour



### Arteriovenous malformations

---

An arteriovenous malformation refers to communication between an artery and a vein. The affected skin feels warmer than the surrounding skin. It may be possible to feel a 'thrill' due to the high flow of blood through the arteriovenous malformation. The doctor listening with a stethoscope may hear a rumble or 'bruit'. These are sometimes associated with other abnormalities in various [vascular syndromes](#).

### Blue rubber bleb naevus syndrome

---

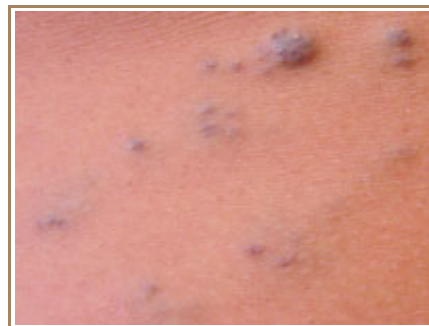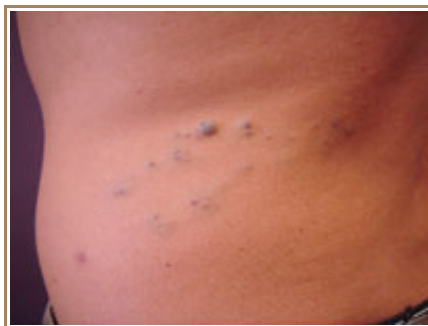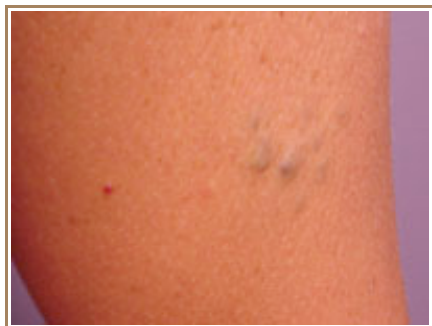The blue rubber bleb naevus syndrome is a rare form of venous malformation in which there are skin and gastrointestinal tract lesions. There is frequently a family history, with autosomal dominant inheritance i.e. the

tendency to the syndrome is passed on to half of one's children.

The skin lesions present as compressible blue or purple rubbery nodules with a wrinkled surface. There may be a single lesion or hundreds of lesions occurring all over the body. Lesions in the GI tract (mouth to rectum) may bleed and cause anaemia or rarely, sudden death. The nodules remain unchanged for life.

[Surgical excision](#), [sclerotherapy](#) and/or [laser therapy](#) may be indicated. However in most cases no treatment is required.

### Blue rubber bleb naevus syndrome



## Maffucci syndrome

Maffucci syndrome is a rare genetic disorder that affects both males and females. It is characterised by cartilage growths (enchondromas), bone deformities, and venous malformations. The disease is present at birth or develops during infancy.

The venous malformations protrude as soft blue nodules on the arms and legs or elsewhere. The enchondromas are often found on the fingers and toes or at the ends of the long bones. Sometimes they result in fractures. Cancer (chondrosarcoma) may arise within the enchondromas in about 30% of adult patients.

## Investigations

Venous malformations are usually diagnosed clinically. However, an ultrasound scan is often performed to find out the extent of the abnormality. Characteristically, a venous malformation shows compressible tubular blood vessels. In some cases, fresh or older calcified blood clots (thrombosis) may be detected.

Ultrasound evaluation of arteriovenous malformations also shows evidence of shunting of blood between the affected artery and vein with turbulent blood flow.

In more complicated cases it may be necessary to perform Magnetic Resonance Imaging (MRI) or angiography to help plan treatment.

## Treatment of venous malformations

Treatment of venous malformations is very difficult and often involves complex surgery and/or ultrasound guided [sclerotherapy](#). Extensive malformations require careful assessment, often by a team of specialists that may include a paediatric dermatologist, paediatrician, radiologist, plastic surgeon and/or vascular surgeon.

### Related information

#### References:

#### On DermNet NZ:

- [Birthmarks](#)
- [Capillary malformations](#)

- [Haemangiomas](#)
- [Lymphangiomas](#) (lymphatic vascular malformations)

**Other websites:**

- [The Hemangioma and Vascular Birthmarks Foundation](#)
- [Sturge-Weber Foundation](#)
- [La Fundación Internacional para la Ayuda contra las Malformaciones Vasculares](#)
- Emedicine dermatology, the online textbook:
  - [Blue rubber bleb nevus syndrome](#)
  - [Glomus tumour](#)

**Books about skin diseases:**

See the [DermNet NZ bookstore](#)

**Author:** [Dr Amanda Oakley](#)

DermNet does not provide an on-line consultation service.  
If you have any concerns with your skin or its treatment, see a [dermatologist](#) for advice.

Created 2003. Last updated 05 Oct 2007. © 2008 NZDS. Disclaimer.